

# Mini implants: a useful complement to conventional implants?

**Authors**\_Dr Friedhelm Heinemann, PD Dr Torsten Mundt & Prof. Dr Christoph Bourauel, Germany

**Fig. 1**\_Finite element model of an experimental mini implant in an idealised bone segment of an anterior mandibular jaw (left). Calculated strains in the implant. The maximum strain level is found in the area where the corticalis is penetrated (red spots in the middle). The picture on the right shows an overhead shot of the corticalis. In the grey area, the bone is overloaded.<sup>5</sup>

## \_Introduction

Mini dental implants with a diameter of less than 3 mm have been used increasingly often in dental implantology. Several years ago, they were typically placed in combination with conventional implants and served as provisional solutions for the stabilisation of dentures during the healing phase.<sup>5</sup> Today, they are also approved for long-term use. On the

one hand, mini dental implants are placed to fix complete or partial dentures and contribute to increased stability. On the other hand, they are used as abutments for fixed bridges in specific situations, e.g. in small gaps.<sup>12</sup>

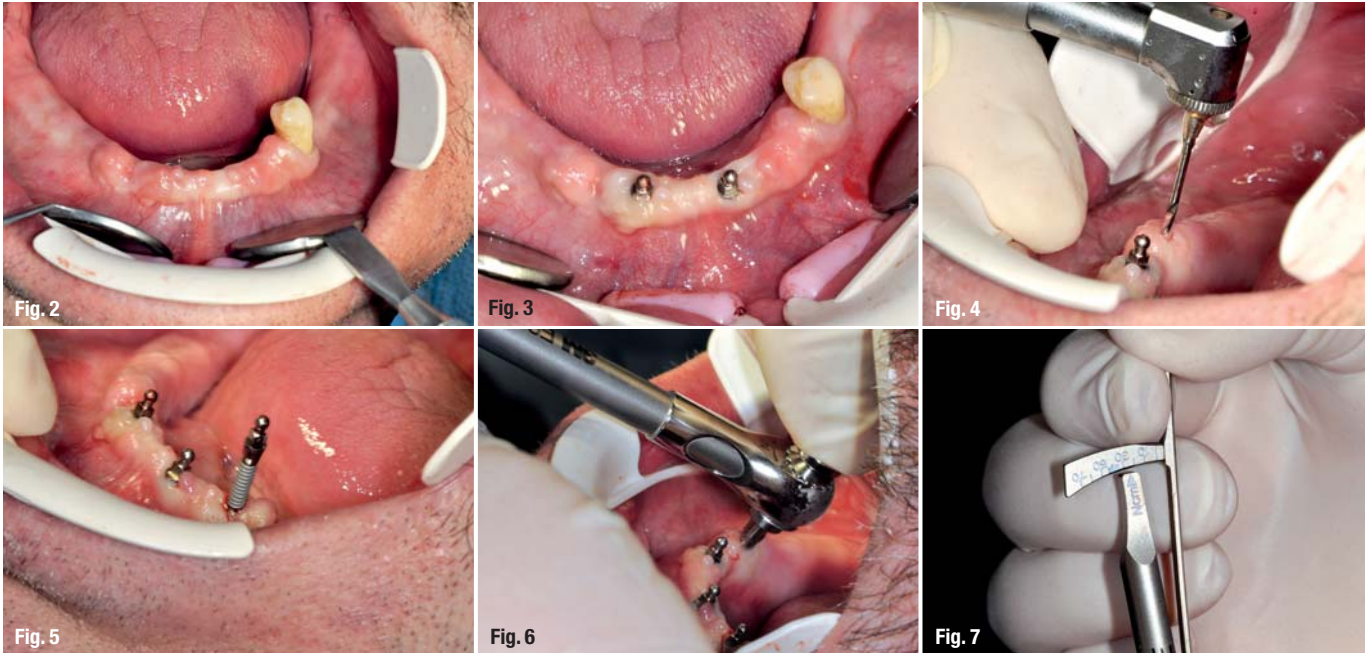
## \_Risks of mini implants

Although one-piece implants have been used for retention of definitive restorations for several years—the first approval was granted in 1997 by the US Food and Drug Administration (FDA) for today's 3M™ ESPE™ MDI Mini Dental Implants—there are still reservations in many practices regarding their suitability for permanent use. This is due to study results which reveal that implants with a reduced diameter might have a higher failure rate than conventional implants.<sup>9,13</sup> In an investigation analysing the biomechanics (FEM analysis) of mini implants, it was shown that, in comparison with conventional implants, those with a small diameter cause a significantly increased stress on the bone.<sup>7</sup>

Figure 1 shows the FE model of an experimental implant. In this investigation, the implants were surrounded by a thin bone segment representing bone loss in analogy with the clinical situation. The corticalis was modelled with a relatively high thickness and the turn of the thread stood in contact with the corticalis. The presumed load was a force transmission of 150 N with an angle of 30° to the implant axis. The load on the implant and the bone under these conditions is represented in Figure 1. While the strains in the implant are 600 MPa and thus below the flow limit of the material, a load on the oral corticalis of up to 200 MPa was measured. This is twice the permissible limit stress for the bone



**Fig. 1**



**Fig. 2**\_Initial situation in the mandible.  
**Fig. 3**\_Situation after placement of two mini implants in the anterior area.  
**Fig. 4**\_Drilling of the pilot hole.  
**Fig. 5**\_Insertion of another implant.  
**Fig. 6**\_Use of the torque wrench.  
**Fig. 7**\_Adjustment of the torque wrench.

(100 MPa) from which damage is to be expected. The investigation was based on the assumption that the same prosthetic concept that used for conventional implants was applied, causing a direct load distribution on the implant.

The observed higher load might be an explanation for the partly increased failure rates. However, a current literature survey shows that the survival rate of implants with a reduced diameter is indeed comparable to the ones obtained for conventional implants.<sup>11</sup> In addition, there are references pointing towards a lower stability of mini implants and those indicating the risk that these might fracture due to their reduced diameter.<sup>1,6</sup> However, these fractures also do not seem to be a frequent problem associated with mini implants.<sup>4,8</sup>

**Alternative solution with reduced bone volume**

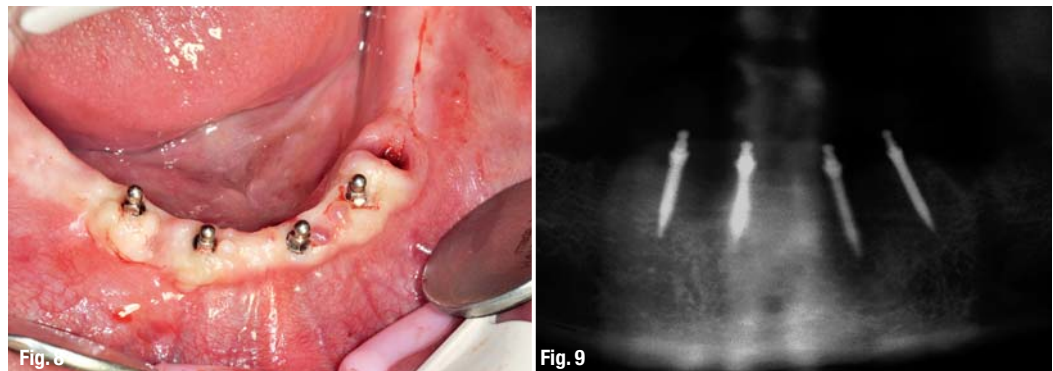
Mini implants prove their worth in the clinical long-term use, provided that they are placed in ac-

cordance with the protocol recommended by the manufacturer and inserted by trained dentists or implantologists.<sup>2,3,10</sup> Under these conditions, they present a sensible supplement to implants with a conventional diameter in many cases.

For example, mini implants are indicated in cases where the horizontal bone volume is not sufficient for conventional implant placement and where bone quality is not impaired. In many cases, augmentative measures or bone splitting would be necessary in order to create sufficient space for the implant. By use of a mini dental implant, a complex augmentation procedure can be avoided and in particular cases, e.g. in medically compromised patients, implant treatment is only possible with implants with a small diameter, since the surgical risk can be reduced this way.

In the following paragraphs, two patient cases are described in which mini dental implants were used for denture stabilisation in the mandible.

**Fig. 8**\_Final situation.  
**Fig. 9**\_Radiograph for checking the final implant positions.



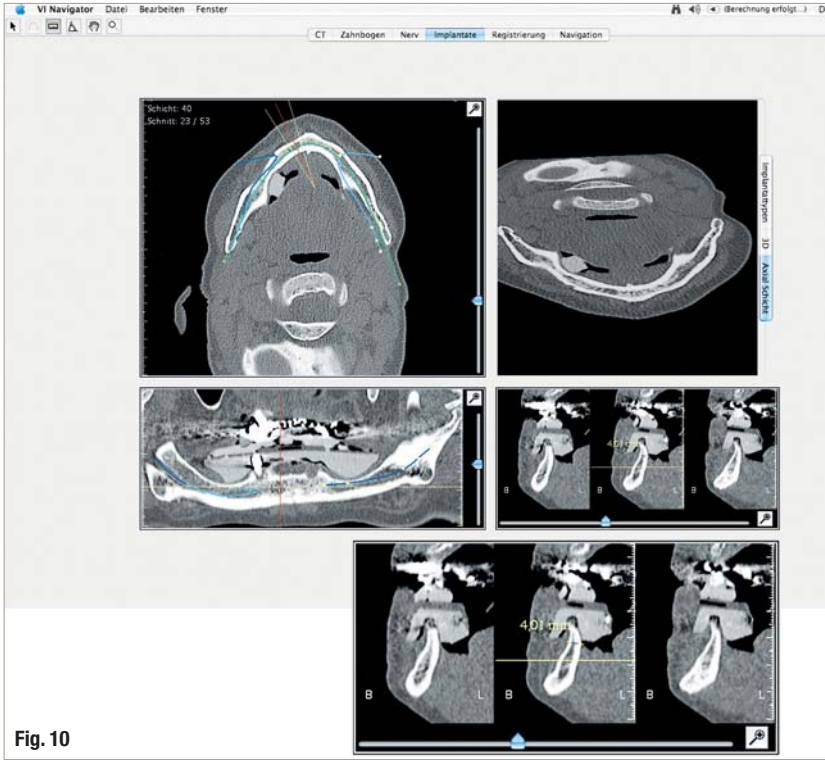


Fig. 10

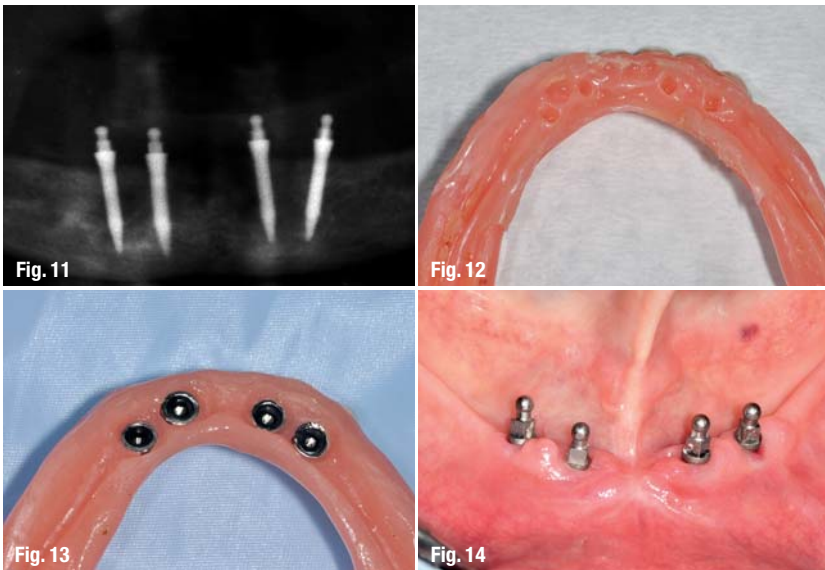


Fig. 11

Fig. 12

Fig. 13

Fig. 14

Fig. 10\_CBCT scan for analysis of the anatomical situation.

Fig. 11\_ Checking of the implant positions on the OPG.

Fig. 12\_ Marking of the implant positions on the denture base.

Fig. 13\_ Basal view of the denture after embedding the metal housings.

Fig. 14\_ Clinical situation in the mandible after placement of four mini implants.

### \_Patient case I

Originally, the male patient had received a partial mandibular denture which was supported by the remaining natural teeth. The remaining premolar (Fig. 2) was not considered to be worth preserving. Since the anxious patient also asked for a treatment with a reasonable price, the placement of four one-piece Mini Dental Implants (3M ESPE MDI) with a diameter of 1.8 mm and an O-ball head was planned. Within the context of the implant procedure, the premolar should be extracted. Due to the low thickness of the gingiva, it was not necessary to create a flap: the location of the bone could be identified exactly. Initially, the desired implant positions

were determined. The positions should be chosen in a way that the mesial distance from the mental foramen and the neurovascular bundle is at least 7 mm. In addition, a gap between the implants of minimally 5 mm is required. In this way, it is ensured that sufficient space is left between the metal housings which are placed on the implants later on and are used for fixation of the denture base.

In the first step, two implants were inserted in the anterior region following the protocol which is recommended by the manufacturer (Fig. 3). For the preparation of the pilot hole, a drill with a diameter that is smaller than that of the selected implant was used. Moreover, the drilling depth should be one half to one third of the implant length in order to cause bone compression and condensation during implant insertion. This contributes to an increased primary stability of the implants and is possible due to the self-tapping design of MDI. For turning the implant, a silicone cap, a finger driver, a winged thumb driver and a torque wrench were used one after the other. All instruments—with the exception of the torque wrench—were used until clear resistance was felt. The insertion of the distal implants followed in the same manner after extraction of the premolar (Figs. 4–6). With the aid of the torque wrench, an insertion torque of 35 Ncm was obtained in order to ensure sufficient stability of the implant (Fig. 7). Figure 8 shows the final situation. On the control radiograph it became clear that the implants were placed in the desired positions (Fig. 9).

### \_Patient case II

In this case, the female patient, approximately 65 years old, was not happy with the stability of her denture. Moreover, she reported that she frequently had sore spots which could be explained by a very narrow and pointed alveolar ridge after the initial clinical examination. The patient obtained detailed information about the situation and the available treatment options and finally settled for three-dimensional radiographic diagnosis in order to lay the foundation for a simplified decision making regarding different prosthetic concepts.

The radiograph (Fig. 10) confirmed a high and entirely small alveolar bone. Without complex augmentative measures, implant placement was not possible. Moreover, it was revealed that, in accordance with the small ridge, the bone was dense and thus ideally suited for the use of mini dental implants—judged by the results of the FEM analysis. Since the patient did not desire complex augmentation procedures, she opted for fixation of a complete denture with MDI Mini Dental Implants.

Four mini implants with a diameter of 2.1 mm and a length of 13 mm were inserted in the mandible following the procedure described above. Their position was checked on the OPG (Figs. 11 and 12). Afterwards, SECURE Soft Reline Material (3M ESPE) was applied into the denture base, which was cautiously placed into the mouth of the patient. In this way, the implant positions were marked in the material (Fig. 13). Subsequently, the metal housings were embedded in the denture base using SECURE Hard Pick-Up Material (3M ESPE). The housings were pressed into the denture intraorally during occlusion. When the cold cure resin was polymerised, the denture was removed from the mouth and finished.

Since the metal housings enable highly elastic anchorage via rubber O-rings, the denture is still supported by the soft tissue and the load on the implants is reduced. Thus, immediate loading is possible if the required primary stability is obtained, as is usually the case in the mandible. The resilient connection concept without contact of metal to metal (soft loading) should also reduce the risk of overload of the implant or the surrounding bone bed as observed in the FEM analysis described above. However, a scientific verification of the interface remains to be done.

## Conclusion

As shown by both patient cases, mini dental implants are a useful alternative or complement to implants with a conventional diameter. The patient is often spared complex augmentative measures which are time-consuming and invasive. In addition, new treatment options are created for medically compromised as well as anxious patients. After a thorough evaluation of the risks and benefits of a treatment involving mini implants and provided that they are placed by an implantologically experienced dentist who follows the insertion protocol, excellent clinical results can be obtained.

*Editorial note: A complete list of references is available from the publisher.*

## \_contact

## implants

### Dr Friedhelm Heinemann

Im Hainsfeld 29  
51597 Morsbach, Germany  
Tel.: +49 2294 9920-10

friedhelmheinemann@web.de

AD

*become an author  
for "implants"*

[PICTURE ©SURYAVAKI]



Please contact Claudia Jahn  
✉ c.jahn@oemus-media.de