

# Advantages of 3-D planning for implants

Authors\_Drs A. Grandoch & P. Ehrl, Germany

## Introduction

Implantology is predominantly a surgical and prosthetic subject area. Its aim is both functional and aesthetic restoration. Today, one can place an implant in the jawbone with a high probability of success if there is good bone support. There are, however, concerns with regard to bone defects, optimum aesthetic and functional positioning of the implant and the soft-tissue situation, possibly requiring partial reconstruction. The ideal number of implants for large superstructures is still a matter of debate.

Functionality, durability and aesthetics are aims that should, in general, be achieved as simply as possible using favourable and conditionally reversible techniques with minimal damage, even in problematic cases. Restoring teeth today has become easier to achieve but whether the cost-benefit ratio is satisfactory must be established for each case. There is still no consensus on these aims and perhaps success can be defined only individually. Expectations regarding implantological solutions have increased owing to significant technological advances. One may distinguish between general success criteria valid for all implants and criteria for special indications. While some scientific societies recommend replacing lost teeth with implants as the optimal treatment, and bearing

in mind that the goal is restoration of natural conditions, one has to ascertain whether this is valid for single-tooth and multiple-tooth replacement for each case. Reasons for suboptimal solutions are manifold, ranging from poor initial conditions associated with a higher treatment risk to socio-economic limitations.

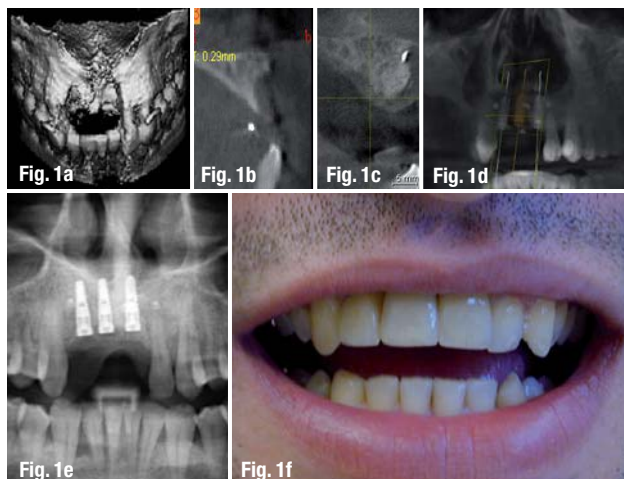
One cannot write about implant treatment in general, as too many parameters play a role, particularly because each case differs from another. Moreover, there are no general recommendations with regard to methodology. This is hardly surprising, since various methods are used, of which many have limited application and quickly become out of date. There is no widely agreed upon gold standard.<sup>1</sup>

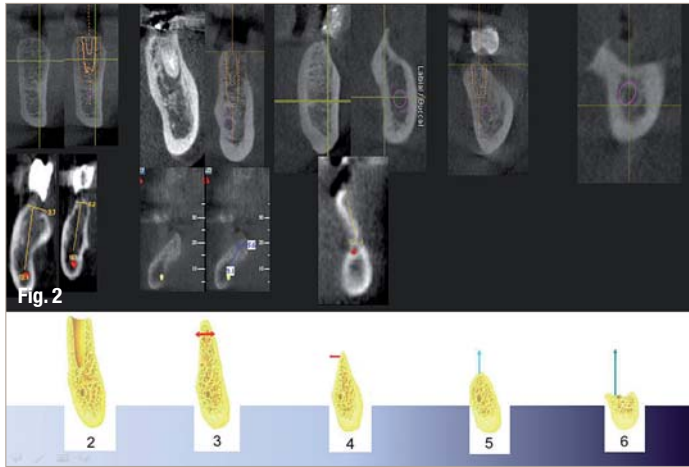
## Methods

In 2000, CBCT was introduced to our clinic with hesitation initially and limited to more extensive problems and progressive diseases. It was used increasingly and has been used for almost all implant surgeries since 2008. Three-dimensional diagnostics undisputedly offer greater insight, thus increasing the quality of the treatment. Three-dimensional planning, however, always means considering the prosthetic planning and the anatomical substratum. This is done digitally or via conventional casts.

Even before the introduction of 3-D technologies, backward planning<sup>2</sup> demonstrated that viewing the desired treatment result is helpful in achieving the result. Here too, we initially applied backward planning to cases requiring extensive treatment at first, until we learned that planning is useful for single-tooth replacement too. Each of these techniques—conventional casts and CBCT scans—can be helpful, contributing to a distinct improvement in the treatment results in the hands of the experienced implantologist. The next step would therefore be to connect these two techniques. After purely digitally controlled navigation was found to be inaccurate, surgical guide systems, based on planning software, became available.

**Figs. 1a-f** Single-tooth replacement with 3-D planning pre- and post-augmentation: Massive defects in the buccal lamella, regions 11 and 21 (a). The dimensions of the defects are visible in the sagittal plane (b). After horizontal bone grafting (c). Three-dimensional planning post-augmentation (d). Post-implantation (e). Patient with crowns (f).





**Fig. 2** Depiction of anatomical varieties in the lateral mandible (classification according to Atwood).

Currently, we are making the step from plaster cast and wax-up to digital model and digital reconstruction. This interesting new approach has to prove its worth in the practice first. Therefore, we have to determine which of the many digital features are essential in treatment of the patient.

### Main features of 3-D planning

Only by the evaluation of 3-D data does a preoperative decision on how the desired prosthetic result can be obtained become possible. With the final result in view and mind, a solid basis for deciding upon the necessity and type of augmentation and whether removable or fixed dentures are indicated in edentulous jaws is provided. There are often bone defects, whose extent must be evaluated. They are classified according to Fallschüssel and Atwood and the classification demonstrates that, as a rule, horizontal bone loss occurs first, while vertical bone is lost gradually.

Restoring horizontal bone is important for prosthetic restoration primarily for aesthetic reasons in the anterior area and primarily for functional reasons in the lateral areas concerning the position of the implant in the dental arch. These defects can be optimally corrected via surgical restoration of the original bone volume. For each case, measurements for posi-

tioning the implant (such as inclination—to be performed by the surgeon) and measurements for the prosthesis (to be done by the dental technician) must be taken. The latter, for example, buccal crown overhangs or mucosal facings, prevent hygienic design of the superstructure and quite often result in aesthetic deficiencies.

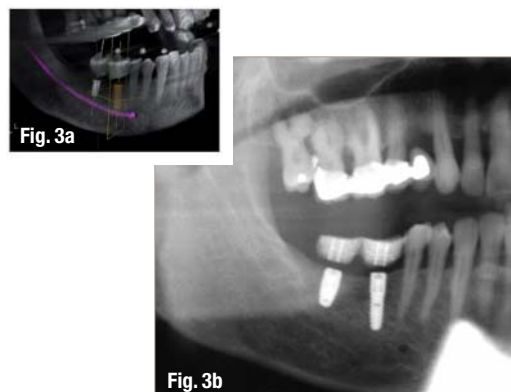
If restoration of vertical bone volume is necessary, for instance with Fallschüssel Class 4 frontal or 2 lateral or Atwood Class 4 defects, a more costly two-step technique has to be followed in most cases. At this point, it should be noted that almost all the atrophy patterns mentioned only involve the jaw and do not concern the functional components of the dental arches. Arutinov et al.<sup>3</sup> postulate that this must be compensated for by angled implants. Kinsel et al.<sup>4</sup> conclude that only the length of the implant is significant for implant loss. This means that as great a bone volume as possible must be used. All of the above-mentioned planning decisions can only be made soundly if information about both the 3-D anatomy and the desired prosthetic solution is available.

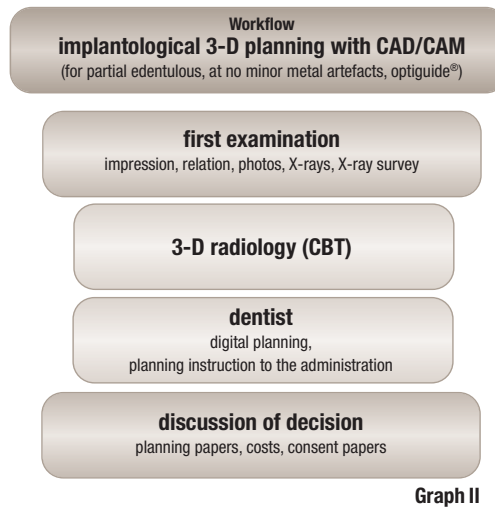
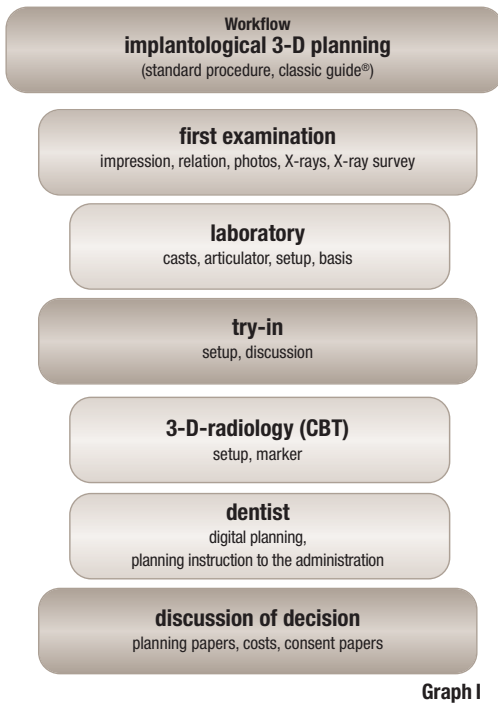
The guidelines of the European Association of Dental Implantologists<sup>5</sup> offer a critical discussion of angled and short implants. Angled implants require a bone quality above 3, 3-D planning and guided implantation, among others. Planning based on an impression with fabrication of a planning cast is critical for the final outcome of implant placement and thus for the procedure. This will determine the required treatment steps and desired treatment outcome. Quite often, this step is not accorded the necessary importance in daily practice. Adequate planning should be done by the dentist and a special appointment with the patient should be made to obtain consent. With two-step procedures, repeating planning after augmentation and a second 3-D radiograph may become necessary.

### Digital 3-D planning

Today's prosthetic planning possibilities offer alternatives to conventional casts. Two digital prosthetic planning tools will be discussed here, SimPlant (Materialise Dental) and SICAT/CEREC (Sirona). Both these tools are alternatives to the conventional approach described above via digital planning. With both methods, the surface of the neighbouring teeth and soft tissue is scanned and matched to the radiological 3-D data. This can be done from a cast (SimPlant and SICAT) or an intra-oral scan (SICAT OPTIGUIDE procedure). Then, a digital cast is created with the prosthetic planning programme. The objectives of these methods are simplification and shortening of the workflow (Graphs I & II).

**Figs. 3a & b** Planning in the lateral mandible with setup cast *in situ* (SICAT) (a). Post-implantation with surgical guide for control (b).





**Graph I**\_Workflow for 3-D implant planning.

**Graph II**\_Workflow for 3-D implant planning with CAD/CAM.

The precision of these methods is particularly noteworthy and figures for the overlap of the radiographic data and the optical scan obtained with the SICAT CAD/CAM method are available. The difference between CBCT data and the optical surface scan is between 0.03 (0.33) and 0.14 (0.18) mm.<sup>6</sup> After scanning, crowns can be planned with the help of the CEREC crowns and bridges planning software. The precision of the digital SICAT method depends on the resolution of the respective data. For analogue impression techniques, for example, a precision between 0.1 and a maximum of 0.2 mm is required,<sup>7</sup> as well as a gap of 0.027 to 0.101 mm between the crown and natural tooth.<sup>8</sup>

The precision of the two methods therefore is similar. This holds true if all error sources are taken into account: CBCT scan, the transfer to the surgical guide, the repositioning of the guide, the play of the drill and deviation when placing the implant. The surface scan improves precision. The advantage of this procedure is that the production of a planning cast is unnecessary (Graph II). The OPTIGUIDE method makes an important step towards the digitisation of prosthetic and implant planning, resulting in greater planning reliability and precision. Unfortunately, there are restrictions concerning partially edentulous jaws and cases with extensive metal artefacts.

### \_Single-tooth replacement

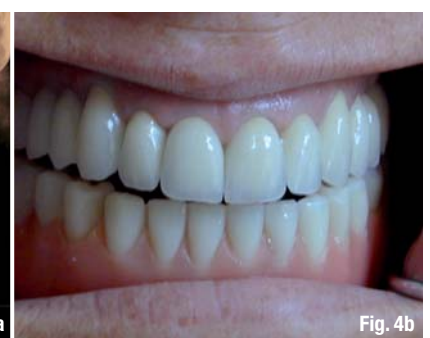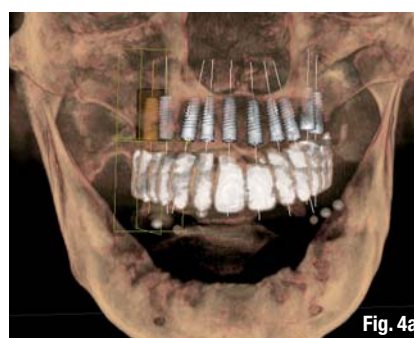
Expectations are high with single-tooth replacement. The target is to achieve a state equal to the conditions before tooth loss. Tooth replacement in the aesthetic region is particularly demanding. Anatomical prerequisites primarily determine the treatment method.

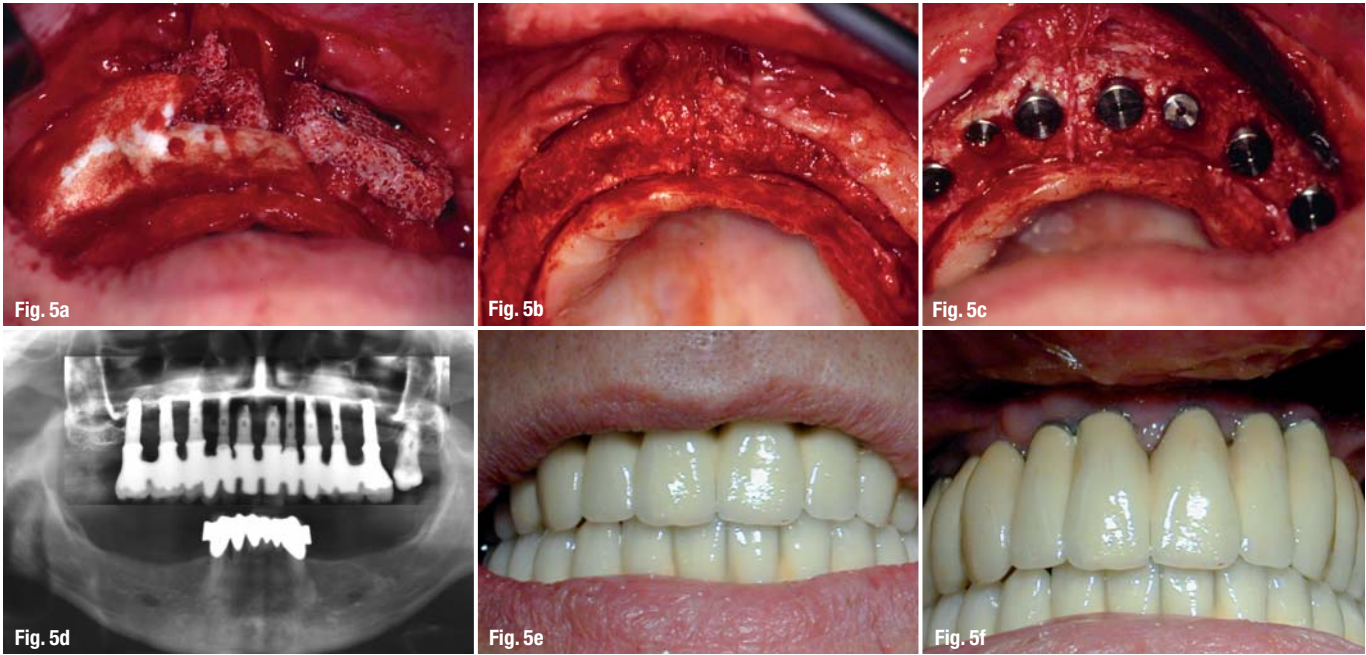
For example, an implant may be placed into a particular alveolus immediately without 3-D planning. For delayed implantation, a cast and 3-D radiograph should be used. By planning the implant inclination and relation to the neighbouring teeth, the emergence profile and the positioning of the crown can be favourably planned. Guided implantation is particularly helpful in individual implants when several individual implants have to be placed or neighbouring teeth are endangered where there is only limited space. In addition, the patient's wish to see the expected outcome can be met. However, visualising optimum results involves the danger of arousing expectations that cannot be guaranteed. Figures 1a to f show the two-step reconstruction of a horizontal defect with 3-D planning.

### \_Shortened row of teeth

In reconstruction of a shortened row of teeth, the function and particularly the support of the tem-

**Figs. 4a & b**\_Three-dimensional planning in an edentulous maxilla (a). Prosthetic loading with good initial conditions (b).





**Figs. 5a–f** Two-step technique in a case of advanced atrophy of the alveolar process before prior to fixed prostheses. Horizontal and vertical augmentation (intra-operatively, fixed bone block (left) and covered with membrane cover (right); **a**). Healed post-augmentation (**b**). Post-implantation (**c**). Radiograph after placement of the bridge (**d**). Prosthetic result, lip repose (**e**). Prosthetic result, lip raised (**f**). Despite augmentation, long crowns are still required.

poromandibular joint is important. The number of teeth necessary for prostheses has not been determined definitively. Within the last few years, reconstructing up to the first molar, and up to the second premolar in cases with an extension, has been usual. Generally, alveolar atrophy progresses most rapidly horizontally in the lateral jaw area, starting buccally, and frequently is later followed by atrophy of the vertical dimension.

If one avoids augmentation or performs only minor augmentation, longer prostheses are necessary for short implants, which are situated more lingually than the natural teeth. The use of short implants in the lateral jaw is subject to several restrictions, such as good bone quality, primarily connected crowns or caps, no extension bridges, no lateral excursion contacts and no para-functional habits. Angulation is limited to 20 degrees. Furthermore, angled implants are not recommended for a shortened row of teeth according to the guidelines of the European Association of Dental Implantologists.<sup>5</sup> If alignment is carried out with respect to antagonists in the natural dentition, positioning the new implant-borne crowns will

not lead to any functional losses, unless the antagonists were not functionally situated in the dental arches originally.

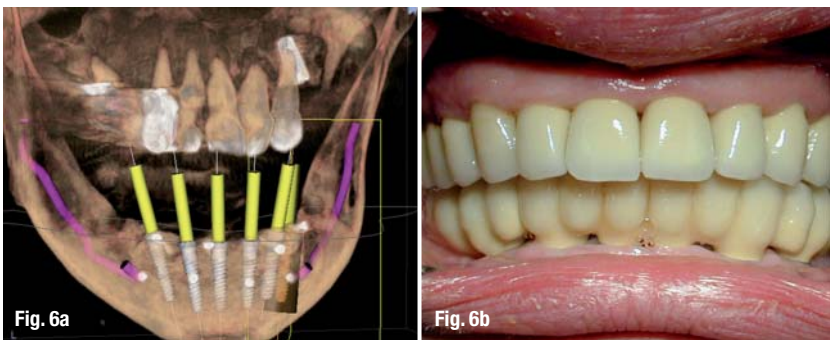
Space towards the cheeks must be regained, even if patients with a long case history sometimes complain about spontaneous cheek biting and bolus retention. One must choose carefully between the more pleasant approach of using short and angled implants with long crowns and the more difficult approach of bone augmentation. Three-dimensional planning provides indispensable information in cases like these. With reference to typical defect patterns, Figure 2 demonstrates that restoring bone volume for very different defects can be problematic. A typical reconstruction using a surgical guide for pilot drillings in a shortened row of teeth with good initial conditions is depicted in Figures 3a and b.

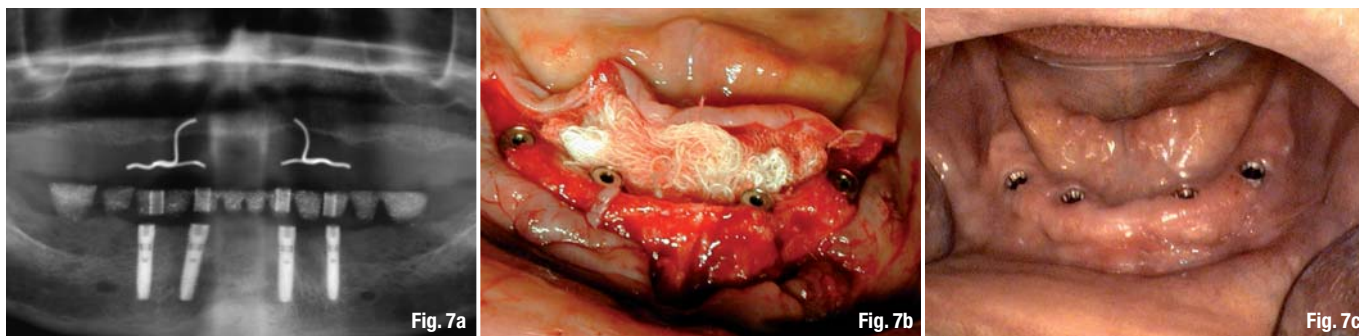
### Edentulous jaw

Three-dimensional planning is of vital importance for determining the treatment approach for implantation in edentulous jaws. For instance, one has to decide upon whether and which augmentative measures are required and whether a removable or fixed prosthesis is suitable. With regard to the last point, it must also be decided whether extensive single-tooth replacement is possible, whether small or large bridges must be used, and whether a greater intermaxillary distance must be filled prosthetically by longer crowns or by a mucosa substitute.

The number of implants for fixed dental prostheses include the All-on-4 concept (Nobel Biocare), the consensus conference recommendations of six im-

**Figs. 6a & b** Loading of an edentulous mandible with a fixed bridge on inter-foraminal implants: Planning detail (**a**). Four years post-treatment (**b**).





plants in the mandible and eight in the maxilla, and tooth-by-tooth reconstruction up to the first molar. The multitude of planning information and treatment possibilities requires a great deal of planning, which is always justified because of its significant consequences. Planning based on digital casts is not appropriate in these cases, since the support of the cheeks and lips by the prosthesis is important and this can only be determined with the help of and for each patient. Here, the advantages of prosthetic planning are particularly evident.

Edentulous jaws often require a special approach (see Figs. 4a & b for an example). Extensive augmentation is frequently necessary (Figs. 5a–f). The required length of the teeth, however, has to be clarified with the patient before treatment and depends on the amount of tooth displayed during lip repose (Fig. 5e). Quite frequently, implants are placed inter-foraminally in the mandible, often because extensive augmentation is still problematic in the lateral mandible. Figures 6a and b show a patient with six implants and an extension bridge.

Even in cases of seemingly simple implantation for removable dentures in an edentulous jaw, 3-D planning and a planning cast are needed to verify functional reconstruction and soft-tissue support. In addition, they can aid determination of the positions of the implants in consultation with the dental technician and planning for adequate space for the attachment box.

### Discussion

Three-dimensional planning for implants holds the advantage of higher quality owing to (a) risk identification; (b) planning reliability; (c) production of near-natural structures; (d) targeted and fast work; (e) patient compliance; and (f) cost transparency. These advantages are largely due to the greater amount and quality of information gained. Three-dimensional diagnostics enable us to obtain reliable information about the condition of the alveolar process and important anatomical structures. With the additional planning cast, information about the restoration of

function and aesthetics is obtained. Combining both information sources will result in optimal treatment planning. In addition, an experienced surgeon can address surprises if the patient is flexible. Intra-operative decisions may also need to be made if unexpected situations arise. Knowledge of 3-D data permits planning, which entails devising a well-considered procedure and obtaining the necessary tools and substitute material, for example suitable implants and bone substitutes. Owing to the traceability of diagnosis and treatment, as well as the resulting safety, patients will regard the procedure particularly positively.

A disadvantage is the higher initial outlay, but this is balanced by increasing use owing to a targeted and quicker workflow and thus less reworking. Implantation always requires a 3-D radiograph. These new techniques have greater logistical requirements than conventional dental procedures do and require extensive involvement of the teams involved in order to achieve treatment success.

It should be borne in mind that every surgery is accompanied by a certain risk in spite of the safety precautions taken. In addition, too much confidence in methodologies may lead to carelessness. Errors may even arise with 3-D planning, which may hold negative consequences for treatment. Therefore, it is important to be familiar with each step and error source and thus expert training is crucial. In addition, maintaining a critical attitude throughout treatment is necessary to avoid errors. The advantages of 3-D planning are so significant that it has become indispensable.

*Editorial note: A list of references is available from the publisher.*

_contact	implants
<p><b>Dr Dr Peter A. Ehrl</b>                  andepend                  Berlin, Germany                    peter.ehrl@andepend.com</p>	

**Figs. 7a–c** X-ray after implantation with mucosa-born drilling template *in situ* (a). Surgical site with lingual position of the medial implants (b). After exposure (c).